

# Wadia Journal of Women and Child Health

## Clinical Image

# Infantile onset achalasia cardia

Ishita Mishra<sup>1</sup>, Abhismita Priyadarshinee<sup>1</sup>, Lakshmi Shobhavat<sup>1</sup>

<sup>1</sup>Department of Paediatrics Medicine, Bai Jerbai Wadia Hospital for Children, Mumbai, Maharashtra, India.

### \*Corresponding author:

Ishita Mishra,  
Department of Paediatrics  
Medicine, Bai Jerbai Wadia  
Hospital for Children, Mumbai,  
Maharashtra, India.

[ishita.paeds@gmail.com](mailto:ishita.paeds@gmail.com)

Received : 04 October 2022

Accepted : 05 November 2022

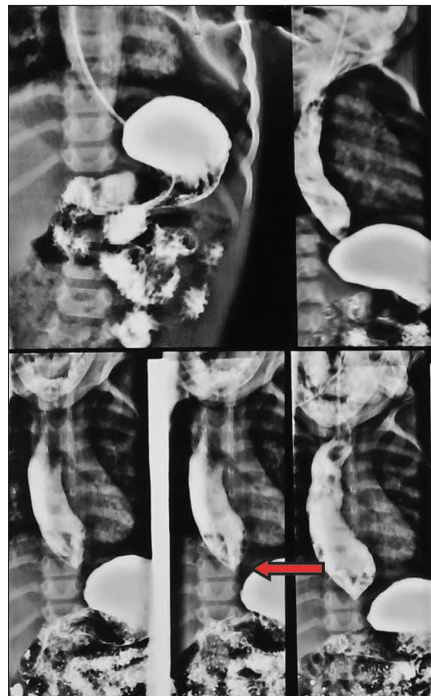
Published : 17 November 2022

### DOI

10.25259/WJWCH\_28\_2022

A 17-month-old girl, born of a third degree consanguineous union, came with the complaints of recurrent fever and cough over the past 6 months for which the patient was advised hospitalization twice. Since 9 months of age child had vomiting which would occur few minutes after feeds and would contain uncurdled milk and later was having cough after multiple episodes of vomiting. On enquiry, there was difficulty in eating solids more than liquids. Parents also noted that the child was not growing well over the past 9 months.

Examination findings revealed severe malnutrition (weight for age, height for age, and weight for height < -3SD) with respiratory findings suggestive of bronchopneumonia. An anatomical defect of the upper gastrointestinal tract (GIT) was suspected and an esophagogram was done. The



**Figure 1:** Obstruction to the passage of barium seen at the GEJ as a smooth tapered narrowing (arrow) suggestive of achalasia cardia.

**How to cite this article:** Mishra I, Priyadarshinee A, Shobhavat L. Infantile onset achalasia cardia. Wadia J Women Child Health 2022;1(2):101-2.

passage of barium through the esophagus was obstructed at the gastroesophageal junction (GEJ) where a smooth tapered narrowing was seen, suggestive of achalasia cardia [Figure 1]. To rule out Allgrove (AAA) syndrome, serum cortisol levels were done, which were normal; however, ophthalmological evaluation showed a decreased tear height.<sup>[1]</sup> Parents were counseled regarding follow-up and genetic evaluation. The child is planned for corrective surgery.

#### **Declaration of patient consent**

The authors certify that they have obtained all appropriate patient consent.

#### **Financial support and sponsorship**

Nil.

#### **Conflicts of interest**

There are no conflicts of interest.

#### **REFERENCES**

1. Sheikh MM, Bittar K. Allgrove syndrome. In: StatPearls. Treasure Island: StatPearls Publishing; 2022.