

# Wadia Journal of Women and Child Health

## Case Report

# A toddler with testosterone: where did it come from?

Amrita Rajiv Mehta<sup>1</sup>, Sudha Chandrashekhar Rao<sup>1</sup>, Rajesh Joshi<sup>1</sup>, Ajinkya Patil<sup>1</sup>

<sup>1</sup>Division of Pediatric Endocrinology, Bai Jerbai Wadia Hospital for Children, Mumbai, Maharashtra, India.

### \*Corresponding author:

Sudha Chandrashekhar Rao,  
Department of Endocrinology,  
Bai Jerbai Wadia Hospital  
for Children, Mumbai,  
Maharashtra, India.

[drsudha1201@gmail.com](mailto:drsudha1201@gmail.com)

Received: 23 August 2022

Accepted: 04 April 2023

Published: 10 October 2023

### DOI

10.25259/WJWCH\_20\_2022

## ABSTRACT

Precocious development of secondary sexual characters not involving pulsatile gonadotropin secretion is known as gonadotropin independent precocious puberty or peripheral precocious puberty (PPP). This form of sexual precocity in males can occur due to gonadal, adrenal, or other testosterone secreting tumors (teratomas, hepatomas, and choriocarcinomas), untreated congenital adrenal hyperplasia, testotoxicosis, and familial male limited precocious puberty. We report a case of a 2-year-old boy with PPP caused due to hepatoblastoma. Complete surgical resection of the tumor was done, and the child received cisplatin chemotherapy.

**Keywords:** Hepatoblastoma, Peripheral precocious puberty, Virilization, B Human Chorionic Gonadotropin

## INTRODUCTION

Precocious puberty (PP), is defined as the appearance of secondary sexual characteristics before 8 years of age in girls and 9 years of age in boys. It could be gonadotropin dependent/central/true precocious puberty where in the premature activation of hypothalamic pituitary gonadal axis leads to raised levels of gonadotropins and gonadal steroids or it could be gonadotropin independent/peripheral/pseudo precocious puberty (GIPP) where gonadal steroids are elevated without activation of the hypothalamic pituitary gonadal axis. Hepatoblastoma is rare and comprises 1% of all pediatric tumors. We present here a boy with peripheral precocious puberty (PPP) GIPP as a manifestation of hepatoblastoma.

## CASE REPORT

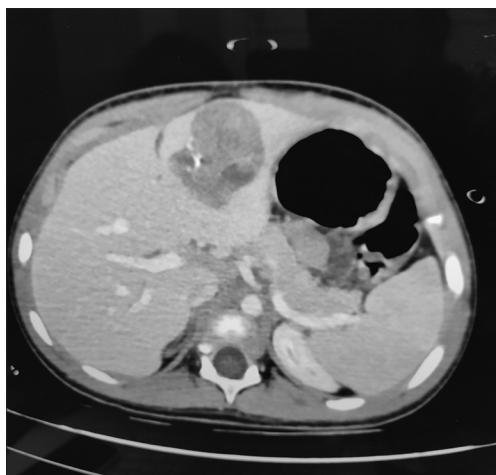
M, a 2-year-old boy, presented to the pediatric endocrine services with features of excessive pubic hair growth for 18 months, penile enlargement and change in voice over 12 months, and appearance of facial hair since past 6 months. The child also had behavioral issues in the form of hyperactivity and temper tantrums. Clinical examination revealed a distended abdomen, signs of rickets, excessive body hair, and a muscular appearance. His weight was 15.2 kg (+2.17 Standard deviation; SD) and height was 90 cm (+1.32 SD) and was above the mid-parental height (+1.01 SD). Genital examination showed penile enlargement with stretched penile length 8 cm, pubic hair of tanner stage 3, and bilateral testicular volume of 3 mL. Systemic examination was suggestive of a palpable liver, 2 cm below the costal margin.

**How to cite this article:** Mehta AR, Rao SC, Joshi R, Patil A. A toddler with testosterone: where did it come from? Wadia J Women Child Health 2023;2(2):93-5.

Investigations revealed an advanced bone age of 5–5.5 years. Both, follicle-stimulating hormone and luteinizing hormone (LH), were suppressed ( $<0.1$  mIU/mL) with elevated serum testosterone of 11.09 ng/mL ( $n$ : 3–9 ng/mL). Further, GIPP work-up revealed normal dehydroepiandrosterone sulfate 13.2  $\mu$ g/dL ( $n$ : 0.47–19.4). Interestingly, serum AFP (Alpha fetoprotein) and b-hCG (beta human chorionic gonadotropin) were raised [AFP - 7719 ng/mL ( $n$ : 0.89–8.78); b-hCG - 876 mIU/mL ( $n$ :  $<1.4$ )]. In view of hepatomegaly and GIPP induced by hCG secreting state with raised AFP, computerized tomography scan abdomen was done which revealed a well-defined,  $4.3 \times 3.9 \times 4$  cm, lobulated heterogeneous hypodense mass of soft-tissue density involving segment III of the liver with heterogeneous post-contrast enhancement and non-enhancing necrotic areas within. Multiple irregular faint and dense areas of calcification were seen within the lesion [Figure 1]. Surgical excision of the mass along with a 1 cm margin of liver was done. Histopathological examination confirmed the presence of a circumscribed, variegated tumor with focal areas of calcification at the periphery. It had an epithelial component which consisted of both embryonal and fetal type differentiation and a mesenchymal component which included mainly mature fibrous tissue and focal osteoid. Tumor cells expressed hepatocyte specific antigen and glypican 3. The hepatoblastoma was of mixed epithelial-mesenchymal type. The child has completed adjuvant chemotherapy (4 cycles of PLADO). He is asymptomatic and recurrence-free 8 months after treatment completion and in close follow up for pubertal issues.

## DISCUSSION

GIPP in male children is commonly due to untreated or inadequately treated congenital adrenal hyperplasia. In a study done by Zou *et al.*, 38.5% of patients with GIPP were



**Figure 1:** Computerized tomography abdomen showing a well-defined heterogeneous soft-tissue density lesion with internal necrotic areas and specks of calcification within segment IV of the liver.

due to adrenal gland disorders.<sup>[1]</sup> hCG-secreting tumors are commonly seen in the testis or ovaries, retroperitoneum, mediastinum, or the central nervous system. hCG secreting hepatoblastomas causing GIPP are rare and only 40 cases have been reported till date.<sup>[2]</sup>

Most cases of hepatoblastoma are diagnosed in children under 18 months of age, and the incidence is 11.2 cases/million. Overall the incidence is 0.5–1.5/million. It is 1.2–3.6 times more common in males. The 5-year survival rate of a hepatoblastoma is 65–75% after resection of the tumor and chemotherapy.

Both hepatoblastoma and GIPP are rare conditions.<sup>[3]</sup> Hepatoblastoma causing isosexual precocious puberty although rare is well described in the literature. The first case of hepatoblastoma with PPP was reported in 1963 by Behrle *et al.*<sup>[4]</sup> Till date, approximately 40 cases have been reported in literature. Majority of the cases were seen in children  $<3$  years of age. b-hCG and AFP levels are elevated in most patients and they are important for diagnosis and follow-up. Features of virilization occur in males due to *de novo* secretion of testosterone<sup>[5]</sup> by the neoplastic cells or due to the effect of b-hCG, which is biologically similar to LH, on Leydig cells of the testis which, in turn, stimulates synthesis of testosterone.<sup>[6]</sup> Treatment of hepatoblastoma resolves the pubertal progression.

## CONCLUSION

GIPP associated with hepatoblastoma is a rare but well documented condition. In children with GIPP, hCG secreting tumors should be evaluated when other causes are not found. An hCG secreting tumor could involve the gonads, adrenals, liver, mediastinum or central nervous system.<sup>[6]</sup> Excision of the tumor is the mainstay of treatment.

## Declaration of patient consent

Patient's consent not required as patients identity is not disclosed or compromised.

## Financial support and sponsorship

Nil.

## Conflicts of interest

There are no conflicts of interest.

## REFERENCES

1. Zou CC, Liang L, Dong GP, Zhao ZY. Peripheral precocious puberty: A retrospective study for six years in Hangzhou, China. *J Paediatr Child Health* 2008;44:415–8.
2. Yhoshu E, Lone YA, Mahajan JK, Singh UB. Hepatoblastoma with precocious puberty. *J Indian Assoc Pediatr Surg* 2019;24:68–71.

3. Marino S, Caruso M, Magro G, D'Amico S, La Spina M, Moscheo C, *et al.* Hepatoblastoma presenting as precocious puberty: A case report. *J Pediatr Endocrinol Metab* 2015;28:429-32.
4. Behrle FC, Mantz FA Jr., Olson RL, Trombold JC. Virilization accompanying hepatoblastoma. *Pediatrics* 1963;32:265-71.
5. Galifer RB, Sultan C, Margueritte G, Barneon G. Testosterone-producing hepatoblastoma in a 3-year-old boy with precocious puberty. *J Pediatr Surg* 1985;20:713-4.
6. Collini P, Pallotti F, Morosi C, Massimino M. Precocious pseudopuberty, a paraneoplastic manifestation: A report of 2 cases. *Tumori* 2020;106:NP14-7.