

# Wadia Journal of Women and Child Health

## Case Series

# Cases series of child abuse needing pediatric intensive care: Hiding in plain sight?

Tasha Vasaya<sup>1</sup>, Rekha Solomon<sup>2</sup> , Shradha Ujjaval Patel<sup>3</sup> , Avinash Shelke<sup>4</sup>, Lakshmi Shobhavat<sup>2</sup> 

<sup>1</sup>Department of Pediatric Intensive Care, Kokilaben Dhirubhai Ambani, <sup>2</sup>Department of Pediatric Intensive Care, Bai Jerbai Wadia Hospital for Children, Mumbai, Maharashtra, <sup>3</sup>Department of Pediatrics, Pramukhswami Medical College, Anand, Gujarat, <sup>4</sup>Department of Pediatric Intensive Care, Aarogyam Women and Child Health Hospital, Aurangabad, Maharashtra, India.

### \*Corresponding author:

Rekha Solomon,  
Department of Pediatric  
Intensive Care, Bai Jerbai Wadia  
Hospital for Children, Mumbai,  
Maharashtra, India.

[rekhasolomon1@gmail.com](mailto:rekhasolomon1@gmail.com)

Received: 03 December 2024

Accepted: 30 January 2025

Published: 15 March 2025

### DOI

10.25259/WJWCH\_51\_2024

## ABSTRACT

Child maltreatment may be in the form of physical, sexual, or emotional abuse or neglect. We present a case series of nine children needing pediatric intensive care unit care due to maltreatment. The children ranged in age from 6 weeks to 7 years. There were 6 boys. Three children were admitted for poisoning (filicide-suicide), four children with traumatic/hypoxic brain injury, one child with burns, and 1 with gunshot injury. Five children died, and one child survived with severe sequelae. In addition, a sibling and three mothers died at other hospitals. One child with poor outcome had a history of admission for similar complaints 2 weeks earlier. A history of family discord or domestic violence was obtained in six cases. There is a need for clinicians to be vigilant in detecting cases of maltreatment before irreparable harm to the child occurs.

**Keywords:** Child abuse, Maltreatment, Non-accidental trauma

## INTRODUCTION

Child abuse or maltreatment is defined by the Indian Academy of Pediatrics as any form of “physical and/or emotional ill-treatment, sexual abuse, neglect or negligent treatment or commercial or other exploitation, resulting in actual or potential harm to the child’s health, survival, development or dignity, in the context of a relationship of responsibility, trust or power.”<sup>[1]</sup> While there are national data on child abuse available from high-income countries, data from low and medium-income countries are mainly in the form of single-center case reports and case series.<sup>[2-4]</sup>

## CASE SERIES

We reviewed children with severe child maltreatment needing Pediatric Intensive Care admission between December 2016 and December 2024. There were nine children ranging in age from 6 weeks to 7 years of age. Three children suffered non-accidental poisoning, and six children suffered physical injury [Table 1]. Majority (6/9) were boys. All the children had normal development and no comorbidities. Five children died, and one survived with sequelae.

**How to cite this article:** Vasaya T, Solomon R, Patel SU, Shelke A, Shobhavat L. Cases series of child abuse needing pediatric intensive care: Hiding in plain sight? Wadia J Women Child Health. 2024;3:126-32. doi: 10.25259/WJWCH\_51\_2024

**Table 1:** Demographics, reason, and outcome of severe maltreatment needing PICU care.

	Age, sex	Injury	Symptoms, presentation	Perpetrator/cause of abuse	Outcome
1.	5-year-old male	Paraquat poisoning	Acute renal failure with progressive liver failure leading to pulmonary alveolar hemorrhage.	Mother, due to familial dispute.	This child, a sibling, and mother died.
2.	7-year-old male	Rat poison ingestion	Liver cell failure with grade 3 encephalopathy.	Mother or father, due to familial dispute.	This child and mother died.
3.	4-year-old male	Rat poison ingestion	Vomiting, jaundice Liver cell failure.	Same as above.	Survived
4.	6-year-old male	Abusive head trauma	Altered sensorium. Multiple bruises, subdural hemorrhage, cerebral edema, tiny retinal hemorrhages, mild subhepatic collection, Rib fractures and metaphyseal fractures of tibia.	Mother's partner who was a migrant worker Mother separated from child's biological father	Died
5.	3-year-old female	Skull fracture with extradural bleed	Loss of consciousness, irritability.	Brought by parents with history of fall from bed while parents were in a fight.	Survived
6.	5-year-old male	Multiple injuries	Posturing following bath. Patterned scald over thigh. Multiple injury marks, scars and bruises. CT brain: Chronic subdural hematoma, ischemic brain injury, tonsillar herniation. Bilateral clavicle fracture. Admission 2 weeks earlier in a different hospital Subdural hemorrhage in brain.	Mother's partner Mother a migrant worker in city. She had left village and child's biological father due to domestic violence.	Survived with severe sequelae.
7.	6-week-old male	Traumatic brain injury/ Suspected shaken baby	Sudden unresponsiveness Multiple subdural hemorrhages, Retinal hemorrhage.	Not known. Mother had old scars on arm, probable cigarette burn.	Died
8.	9-month-old girl	Burns	> 90% burns.	Alleged un-witnessed gas cylinder blast. Kerosene aspirated from stomach.	Mother and child expired
9.	4-year-old girl	Gunshot injury	Gunshot wound left infraclavicular area.	Domestic dispute.	Needed surgery for recovery of shrapnel.

PICU: Pediatric intensive care unit, CT: Computed tomography

### Case 1

A 5-year-old boy brought 8 days after alleged ingestion of paraquat. Detailed questioning revealed that the mother gave her two children the toxin and took it herself following a family dispute. On admission, he had breathing difficulty. His blood tests showed blood urea nitrogen (BUN) 206 mg/dL, creatinine 7.5 mg/dL, serum glutamic pyruvic transaminase (SGPT) 250 U/L, and international normalised ratio (INR) 3.4. His chest X-ray showed bilateral infiltrates. He required mechanical ventilation and succumbed due to refractory hypoxemia.

### Cases 2 and 3

Two siblings were referred 1 day after alleged consumption of rat poison. Both children had features of acute liver cell

failure, and one child needed mechanical ventilation and subsequently succumbed. A parent gave them the toxin during a family dispute, the exact details of which were not clear. The younger child said that father had given them the poison. The father was absconding. In case 2, the mother, who had denied any involvement and was the main caretaker of the children during their hospital stay, suddenly collapsed on 3<sup>rd</sup> hospital day and succumbed to liver cell failure.

### Case 4

A 6-year-old boy was brought with an alleged history of loss of consciousness following fall in the bathroom. The child was admitted with Glasgow Coma Scale 3 and needed measures to treat raised intra-cranial pressure (ICP). He was found to

have multiple bruises, including bruises over his back, limbs, shoulder, chest, and forehead. He had cerebral edema, subdural hemorrhage, and skull fractures on computed tomography (CT) scan [Figure 1]. He had bilateral retinal hemorrhages as well as sub-hepatic hematoma. The child succumbed to his injuries.

There was a changing and inconsistent history. It was subsequently found that the mother's partner who brought the child to hospital along with mother was not the child's biological father. The mother with her two children had migrated to the city with her new partner who worked as a construction worker.

#### Case 5

A 3-year-old girl was brought with a history of brief loss of consciousness and irritability following fall from the bed allegedly while the parents were in an argument. However, history was changing and inconsistent with the findings. CT brain showed a skull fracture and subdural bleed. She was alert with no focal neurological deficits and no other injuries.

#### Case 6

A 5-year-old boy was brought by his mother with posturing and loss of consciousness following a bath. On admission, the child was posturing and unable to maintain airway. He needed intubation and measures to control raised ICP.

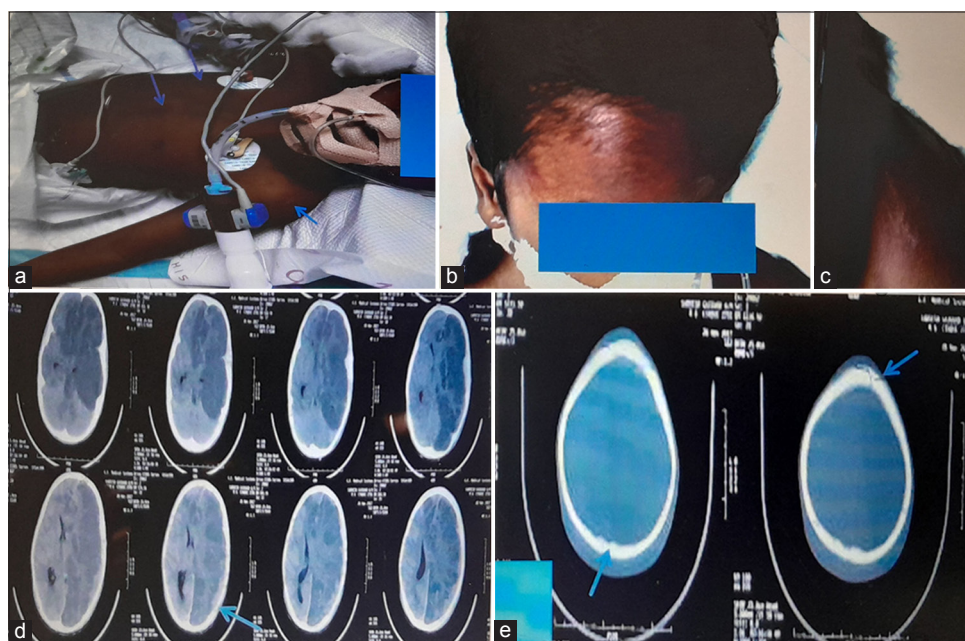
Clinical examination showed multiple crescent abrasions around the neck (0.5–1 cm × 0.2–0.3 cm), abrasions over the right side abdomen and left leg, spindle-shaped thermal burn on the thigh, ulcer and healed scars around the anus, and multiple healed scars (left eyelid, back, and limbs). His CT head showed subdural hemorrhages of different ages, cerebral edema, and tonsillar herniation [Figure 2]. Chest X-rays showed bilateral clavicular fractures.

History revealed that the mother was verbally and physically abused by the child's biological father when he was drunk. The mother had lodged a police complaint and they had separated 3 years earlier; the father and paternal grandmother returned to their village with the child. A few months ago, the villagers contacted the mother and asked her to take the child as he was being physically abused by the father who was an alcoholic. She then brought him to the city and during her working hours, she left him in the care of her current partner.

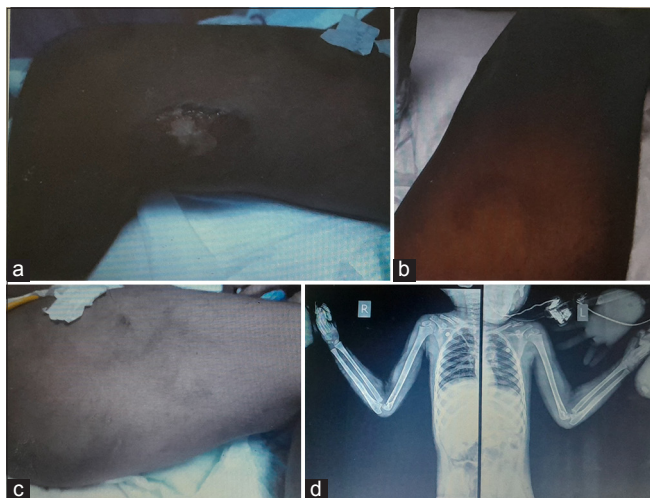
The child had a prolonged intensive care unit (ICU) course and needed tracheostomy. At discharge, he was unaware of his surroundings and dependent on caregivers.

#### Case 7

A 6-week-old boy was brought to hospital after being found unresponsive at home. Family consisted of parents, 1-year-old sibling and this infant who all lived in one room. The family denied any history of shaking, fall, or other trauma.



**Figure 1:** A 6 year old boy with alleged unwitnessed fall in bathroom followed by loss of consciousness. (a-c) Bruises over anterior chest wall, forehead and right shoulder (blue arrows). (d) Computed tomography brain showing frontoparietal hypodensities and left subdural hemorrhage (blue arrow). (e) Occipital and frontal skull fractures (blue arrows).



**Figure 2:** A 5 year old boy with alleged history of fall after bath with loss of consciousness. (a) Patterned thermal burn right thigh. (b and c) Bruises anterior and lateral aspect right thigh. (d) Fracture both clavicles.

The mother had returned 2 weeks earlier, following delivery at her maternal home in another state. The family had no relatives living nearby.

The baby was admitted in altered sensorium, with poor respiratory effort needing intubation. Indirect ophthalmoscopy showed retinal hemorrhages. Complete blood count and coagulation profile were normal. CT brain showed subdural hemorrhage and cerebral edema.

MRI brain showed diffuse restricted diffusion involving both cerebral hemispheres and basal ganglia and thalami. There were multiple extra-axial and parenchymal hematomas with diffuse cerebral edema and trans-tentorial and tonsillar herniation [Figure 3]. X-rays did not reveal other fractures. Parents denied shaking or dropping the baby. The mother had small healed circular scars on her fore arms. The child was managed with mechanical ventilation and measures to treat raised intracranial pressure, but he did not improve and succumbed after 2 days.

#### Case 8

A 9-month-old baby was brought in moribund condition with >90% burns following alleged burst of gas cylinder while at home with her mother. There was a strong smell of kerosene on her body and kerosene was aspirated from her stomach. She succumbed shortly after admission. Her mother who was admitted at another hospital with severe burns also succumbed.

#### Case 9

A 4-year-old girl was brought following alleged gunshot injury during a family dispute. The child's mother had recently returned with her children to her maternal home due to

domestic violence. The child's father went there with a gun. During an altercation with the child's maternal uncles, the child was allegedly accidentally shot near her left shoulder.

On admission to hospital, she was found to have an entry wound in the left infraclavicular region but no exit wound. X-ray chest revealed shrapnel near the median end of clavicle. This was removed surgically and she had an uneventful recovery.

## DISCUSSION

We present nine children who presented following maltreatment through physical trauma, burns, gunshot injury, and poisoning. Although there was a male preponderance (6/9), this may be due to admission bias. Studies have shown both sexes to be equally at risk of intentional harm. Out of nine children, five died and one survived with severe sequelae. In addition, a sibling and three mothers died.

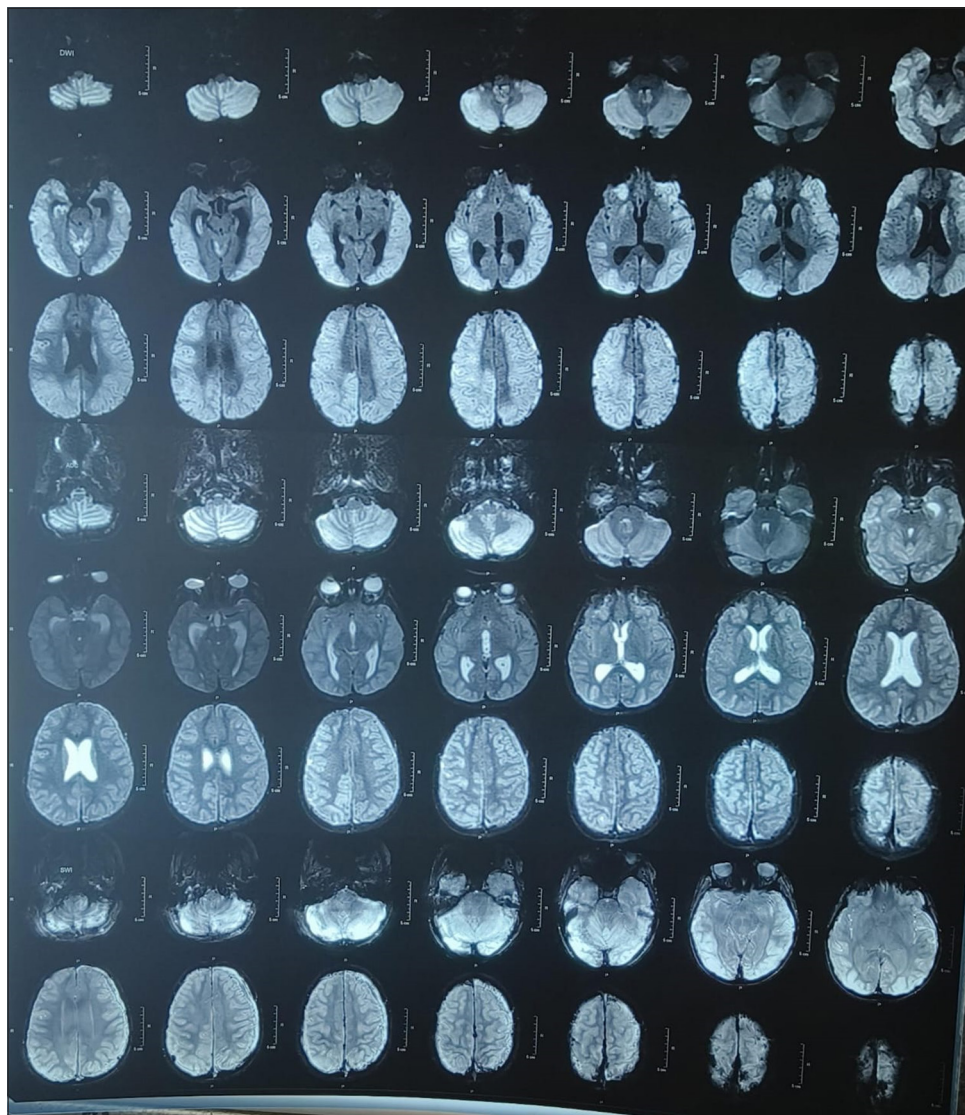
History of family discord and/or domestic violence was obtained in six cases. Intimate partner violence or domestic violence has been shown to be associated with child abuse.<sup>[5-7]</sup> History of migration for work was found in three cases. Studies have shown that while abuse may occur in any social or economic class, unemployment and lack of social or family support are known risk factors for abuse.<sup>[8]</sup> Increasing migration for employment is leading to nuclear families with loss of the usual support structure of extended families and neighbors.

There were two sets of families where the mother fed her children the toxin and then consumed it herself. Filicide suicide is a type of homicide-suicide death that refers to cases where the parent kills the child and then commits suicide. It has been shown to be associated with mental health illness, domestic abuse, and substance abuse. In case of the child admitted with severe burns, it was not known if the perpetrator was the mother or someone else.

It is very important to identify non-accidental injury on the first presentation to medical care as failure to do so may lead to continued abuse as seen in case 6 and severe morbidity or death. A 5-year retrospective chart review of 173 children <3 years old with abusive head trauma found that nearly a third of children (54/173) were missed on initial presentation to hospital and 15 children were re-injured after the first hospital visit.<sup>[9]</sup> Approximately a third of children diagnosed with child maltreatment in the emergency department may need intensive care admission.<sup>[10]</sup> There is a dearth of knowledge on the burden of non-accidental injury presenting to emergency care in our country.

Small infants presenting as unexplained acute life-threatening event such as case 8 have been reported by others as well.<sup>[11]</sup> It is important to do retinal examination and skeletal survey in such children.





**Figure 3:** A 6 week old boy found unresponsive. Magnetic resonance imaging brain showing restricted diffusion both cerebral hemispheres, basal ganglia and thalami.

An important red flag pointing to intentional harm includes circumstance or mechanism of injury not fitting with the developmental age or injury seen in the child [Table 2]. Other red flags include inconsistent or changing history and certain injuries that are highly specific for abuse; these include fractures such as metaphyseal or corner fracture of long bones, fracture of posterior medial ribs, vertebral and complex skull fractures, multiple fractures of different ages, and patterned injuries and injuries in unusual areas of the body and retinal hemorrhages. Severe multi-layered retinal hemorrhages extending to the periphery of the retina as well as retinoschisis are specific for abuse.<sup>[12]</sup> Indirect ophthalmoscopy with dilated pupil is needed as there may be peripheral retinal hemorrhages which may otherwise be missed. Neuroimaging in abusive head trauma may reveal

subdural, subarachnoid, or parenchymal hemorrhage and/or hypoxic injury.<sup>[13]</sup> Shaken baby syndrome may present with a triad of encephalopathy, subdural hemorrhage, and retinal hemorrhage as seen in case 7 of our series. Some children may be seen in emergency room or only by other specialties such as general surgery, plastic surgery (scald or thermal burns), orthopedics (fractures), or neurosurgery.

While being vigilant not to miss cases of abuse, it is important not to wrongly label certain medical conditions as abuse. Subdural hemorrhage with trivial trauma can be caused by conditions such as glutaric aciduria and factor 13 deficiency. Fractures may be seen in children with osteogenesis imperfecta. Children with developmental delay and cerebral palsy are particularly challenging. They are at higher risk of accidental injury with fractures as they may have osteoporosis as well as

**Table 2:** Red flags and mimics for child abuse.

Red flags for abuse	
History	Not fitting with circumstances or mechanism of injury Not fitting with developmental age of child Inconsistent/changing
Bruises/injuries/scalds	Patterned Unusual areas of body
Fractures	Metaphyseal or corner fracture of long bones Fracture of posterior medial ribs Vertebral and complex skull fractures Multiple fractures involving more than 1 skeletal area Fractures of different ages
Fundus	Multilayered retinal hemorrhages extending to the periphery of the retina Retinoschisis
Child abuse mimics	
Multiple bruises	Coagulopathy
Subdural hemorrhage following trivial trauma	Glutaric aciduria and clotting factor deficiency
Multiple fractures	Osteogenesis imperfecta, severe osteoporosis with Vitamin C and/or D deficiency

Vitamin C and or D deficiency. They are also at high risk of non-accidental injury due to caregiver stress along with the inability to protect themselves or communicate with others.

In India, there is no way to ascertain the exact incidence of non-accidental trauma as they are hardly reported and there is no system in place for surveillance of the same. A study in 2007 which defined child abuse as “intended, unintended, and perceived maltreatment of the child” surveyed 12,247 children aged 5–18 years from 13 states in India and found 69% to have faced physical abuse.<sup>[14]</sup>

A cross-sectional survey of 6957 school-going adolescents in Kerala showed a high (89.9%) prevalence of abuse with physical and emotional abuse being the most common.<sup>[15]</sup>

In low and medium income countries (LMICs) such as ours, certain cultural practices and norms such as branding, corporal punishment, and preference for a male child as well

as socioeconomic realities such as street children, child labor, and child trafficking increase the risk of adverse childhood experiences.<sup>[16]</sup>

When child abuse is suspected, detailed assessment, documentation, reporting to the police and Child and Women cell, and ensuring safety of the child are paramount. Child helplines, police force, criminal justice system, and the community all have a role in ensuring safety of the victim.<sup>[1,17]</sup>

This study has several limitations. This is a retrospective case series from a single-center pediatric ICU (PICU). There may be missing data. Cases of neglect may have been missed. The follow-up and outcome (forensic, legal) are not known.

## CONCLUSION

This case series from PICU showed two thirds of cases having poor outcome with severe morbidity or mortality. Child maltreatment needs to be prevented or diagnosed early. Clinicians must be aware of such cases as they are usually caught off guard, and thus, the child may be discharged back to the same environment again resulting in harm. Let the eye of vigilance never be closed.

## Ethical approval

Institutional Review Board approval is not required.

## Declaration of patient consent

The authors certify that they have obtained all appropriate patient consent.

## Financial support and sponsorship

Nil.

## Conflicts of interest

There are no conflicts of interest.

## Use of artificial intelligence (AI)-assisted technology for manuscript preparation

The authors confirm that there was no use of artificial intelligence (AI)-assisted technology for assisting in the writing or editing of the manuscript and no images were manipulated using AI.

## REFERENCES

1. Aggarwal K, Dalwai S, Galagali P, Mishra D, Prasad C, Thadhani A, *et al.* Recommendations on recognition and response to child abuse and neglect in the Indian setting. *Indian Pediatr* 2010;47:493-504.
2. Jayakumar I, Ranjit S, Gandhi D. Shaken baby syndrome. *Indian Pediatr* 2004;41:280-2. Erratum in: *Indian Pediatr*

- 2004;41:357. Jayakumar, Idira [corrected to Jayakumar, Indira].
3. Jose B, Sankhyan N, Arya R, Kabra M, Gulati S, Azad RV. Inflicted neuro-trauma in infancy. *Indian J Pediatr* 2010;77:318-20.
4. Sriram K, Rathnavel S, Papakumari M, Somasundaram O. Battered baby syndrome: A review of eight cases. *Ann Acad Med Singap* 1981;10:466-71.
5. Ahmadabadi Z, Najman JM, Williams GM, Clavarino AM, d'Abbs P, Abajobir AA. Maternal intimate partner violence victimization and child maltreatment. *Child Abuse Negl* 2018;82:23-33.
6. Liel C, Ulrich SM, Lorenz S, Eickhorst A, Fluke J, Walper S. Risk factors for child abuse, neglect and exposure to intimate partner violence in early childhood: Findings in a representative cross-sectional sample in Germany. *Child Abuse Negl* 2020;106:104487.
7. Debelle G, Efstathiou N, Khan R, Williamson A, Summan M, Taylor J. The typology and topography of child abuse and neglect: The experience of a tertiary children's centre. *Int J Environ Res Public Health* 2022;19:8213.
8. Younas F, Gutman LM. Parental risk and protective factors in child maltreatment: A systematic review of the evidence. *Trauma Violence Abuse* 2023;24:3697-714.
9. Jenny C, Hymel KP, Ritzen A, Reinert SE, Hay TC. Analysis of missed cases of abusive head trauma. *JAMA* 1999;281:621-6. Erratum in: *JAMA* 1999;282:29.
10. Akkaya B, İnan C, Ünlü İİ, Güneylüoğlu MM, Bodur İ, Göktuğ A, *et al.* A silent scream in the pediatric emergency department: child abuse and neglect. *Eur J Pediatr* 2024;183:2905-12.
11. Ray M, Ghosh D, Malhi P, Khandelwal N, Singhi PD. Shaken baby syndrome masquerading as apparent life threatening event. *Indian J Pediatr* 2005;72:85.
12. Hansen JB, Killough EF, Moffatt ME, Knapp JF. Retinal hemorrhages: Abusive head trauma or not? *Pediatr Emerg Care* 2018;34:665-70.
13. Pendharkar H, Jabeen S, Pruthi N, Narasinga Rao KV, Shukla D, Kamble N, *et al.* Abusive head trauma in India: imaging raises the curtain. *Int J Inj Contr Saf Promot* 2022;29:103-11.
14. Kacker L, Varadan S, Kumar P. Save the children, ministry of women and child development, Government of India; 2007. Available from: <https://resourcecentre.savethechildren.net/pdf/4978.pdf> [Last accessed on 2024 Nov 28].
15. Kumar MT, Kar N, Kumar S. Prevalence of child abuse in Kerala, India: An ICAST-CH based survey. *Child Abuse Negl* 2019;89:87-98.
16. Singhi P, Saini AG, Malhi P. Child maltreatment in India. *Paediatr Int Child Health* 2013;33:292-300.
17. Dinesh T, Ayilliath A, Ephraim R, Parikkal R. Laws of child abuse in Indian perspective: A review. *J Family Med Prim Care* 2023;12:856-62.